

REPORTE DE CASO

Nódulo de la Hermana María José: un reporte de caso

Sister Mary Joseph's Nodule: A Case Study / Nódulo da irmã Maria José. Um reporte de caso

Lina Marcela Giraldo Rendón¹, Marcela Riveros², Alejandro Vélez Hoyos³

Fecha de recibido:
15 de mayo de 2012
Fecha de aprobación:
11 de diciembre de 2012

RESUMEN

El nódulo de la Hermana María José se refiere a una metástasis de una neoplasia visceral a ombligo más común de origen gastrointestinal. La importancia de esta lesión es que es de fácil aproximación por el examen físico y su alta asociación con neoplasias malignas intra abdominales y la sencillez para hacer el diagnóstico con métodos como la biopsia aspiración con aguja fina.

Palabras clave: biopsia por aspiración con aguja fina guiada por ultrasonido endoscópico; neoplasias gastrointestinales

ABSTRACT

Sister Mary Joseph's nodule refers to the metastasis of visceral malignancy to the umbilicus, most commonly of gastrointestinal origin. The noteworthy characteristics of this lesion are its more approachable diagnosis on physical examination, its high association with intra-abdominal malignancy, and its faculty to provide a diagnosis with easily performed methods such as fine needle aspiration biopsy.

Keywords: endoscopic ultrasound-guided fine needle aspiration; gastrointestinal neoplasms.

RESUMO

O nódulo da irmã Maria José se refere como uma metástase de uma neoplasia visceral a umbigo mais comum de origem gastrointestinal. A importância desta lesão é que é de fácil aproximação pelo exame físico, e sua alta associação com neoplasias malignas intra abdominais e a facilidade para realizar o diagnóstico com métodos fáceis de realizar como a biopsia aspiração com agulha fina.

Palavras chave: aspiração por agulha fina guiada por ultrassom endoscópico; neoplasias gastrointestinais.

INTRODUCTION

Sister Mary Joseph's nodule is the eponym used to describe the cutaneous metastasis to the umbilical area of a malignant neoplasm. The eponymous term was described in honor of Sister Mary Joseph who was the first to observe the presence of nodules within the umbilical

area as being a clinical sign of advanced neoplastic disease.

Sister Mary Joseph was born in 1856 in Salamanca, New York and joined the religious mission at the age of 22. She worked at Saint Mary's Hospital (presently the Mayo Clinic) in Rochester, Minnesota^{1,2} as a surgical assistant for Dr. William Mayo. Through her experience with surgical patients, she noticed

1. Residente de cirugía general, Universidad Ciencias de la Salud. Medellín, Colombia
2. Fellow patología quirúrgica, University of Massachusetts Amherst, Estados Unidos
3. Patólogo Hospital Pablo Tobón Uribe y Dinámica IPS. profesor de patología, Universidad Pontificia Bolivariana, CES y Universidad de Antioquia. Medellín, Colombia

Dirección de correspondencia: Alejandro Vélez Hoyos. Correo electrónico: alejovelez28@hotmail.com

a relationship between the umbilical mass lesion with advanced neoplastic diseases and unfavorable prognosis of the neoplastic processes within the abdominal cavity.

In 1949, Hamilton Bailey used this eponym in his book "Physical signs in clinical surgery" to describe umbilical metastasis in honor of Sister Mary Joseph³⁻⁵

She died at the age of 82 of bronchopneumonia and, according to some reports, noticed the presence of the nodule in herself.

The cutaneous metastasis from malignant neoplasms occurs in 1% to 9% of patients.

Umbilical neoplastic nodules can be due to a primary tumor in 38% of cases (mostly epidermoid type), due to endometriosis in 32% of patients, and in 30% of cases secondary to metastasis from a primary tumor elsewhere.

Metastasis to the umbilicus is associated with a primary tumor in the gastrointestinal tract in 35% to 65% of cases (most commonly gastric cancer, colon cancer, or cancer of the body/tail of the pancreas); 12% to 35% are secondary to a tumor in the genitourinary tract (primarily ovarian cancer and uterine cancer); 3% to 6% originates from hematological malignancies, lung and breast cancers⁶⁻⁹.

In 15% to 30% of patients, the source of the primary site of the tumor remains unknown.

Sister Mary Joseph's nodule presents as a painful lump bulging into the anterior abdominal wall surrounding the umbilical area. It has irregular margins and a hard fibrous consistency. It ranges from 1 to 1.5 cm in diameter, but can occasionally be as large as 10 cm. The cut surface may be ulcerated and necrotic, with either blood, serous, purulent, or mucous discharge.

The differential diagnosis includes non-metastatic diseases like umbilical hernia, hypertrophic scar, pyogenic granuloma, and pilonidal sinus.

When Sister Mary Joseph's nodule is found in a patient, it is necessary to obtain a diagnosis by fine needle aspiration biopsy (early and easy diagnosis) to determine the pathological nature of the lesion. High-resolution ultrasound may be needed before biopsy to clarify the clinical findings by detecting solid umbilical nodules¹⁰⁻¹².

It is also important to have a careful examination and more extensive imaging studies of the abdominal and pelvic contents to look for possible sites of primary tumors.

If the fine needle aspiration biopsy is negative, a biopsy can be performed.

Sister Mary Joseph's nodule usually indicates a poor prognosis. It is a sign of advanced neoplastic disease and may not be amenable to surgery. The survival of these patients without treatment has been reported to range from 2 to 11 months from the time of the initial diagnosis, but the etiology of the primary malignancy determines the prognosis¹²⁻¹⁴.

CASE REPORT

We present a 65-year-old woman with a history of weight loss and gastric symptoms. She was markedly pale and asthenic on her physical examination. Her general physical examination revealed a visible, firm, 2.0 x 2.0 cm periumbilical node.

The fine needle aspiration of the umbilical node showed ring cells of adenocarcinoma (figure 1).

An ultrasound of the abdomen revealed nodes in the liver; an upper gastrointestinal endoscopy demonstrated a ring cell adenocarcinoma in the cardias (figure 2).

DISCUSSION

A full understanding of the mechanisms whereby the tumor spreads to the umbilicus remains unclear. However, following anatomical criteria, several hypotheses have been proposed.

The umbilical ring is a scar invaginated on the abdominal wall between the transversalis fascia and the peritoneum. After birth, the fetal cord structures develop into ligaments or peritoneal folds: 1) median umbilical ligament secondary to the obliterated urachus, 2) medial umbilical ligaments (which are obliterated umbilical arteries), 3) ligamentum teres (obliterated left umbilical vein) that continues into 4) the falciform ligament. On the lateral umbilical folds the inferior epigastric vessels and, sometimes, a vestigial vitelline duct connecting the umbilicus to the ileum can be recognized. The umbilical region shows a rich arterial supply that includes the inferior epigastric and deep circumflex iliac branches of the external iliac artery, and the superior epigastric branch of the internal mammary artery^{13-15,17}.

The venous drainage includes several anastomotic branches, coming cranially from the axillary vein, through the internal mammary vein, and caudally, from the femoral vein through the superficial epigastric vein. In addition, the umbilicus may be connected with the portal system, through small umbilical veins.

The lymphatic system connects the umbilical region to the axillary, inguinal, and para-aortic lymph nodes. The deep lymphatic system passes along the falciform ligament, pierces the diaphragm and enters the anterior mediastinum or courses to the nodes around the iliac arteries^{18,19}.

All these systems (arterial, venous, and lymphatic) as described, represent possible routes by which metastatic tumor cells could implant into the umbilical region.

It is reasonable to suggest that direct extension of tumor through the peritoneum is the preferred route for gastrointestinal tumors. Furthermore, the common association between hepatic and umbilical metastases might suggest the hypothesis of the cancerous cells spreading

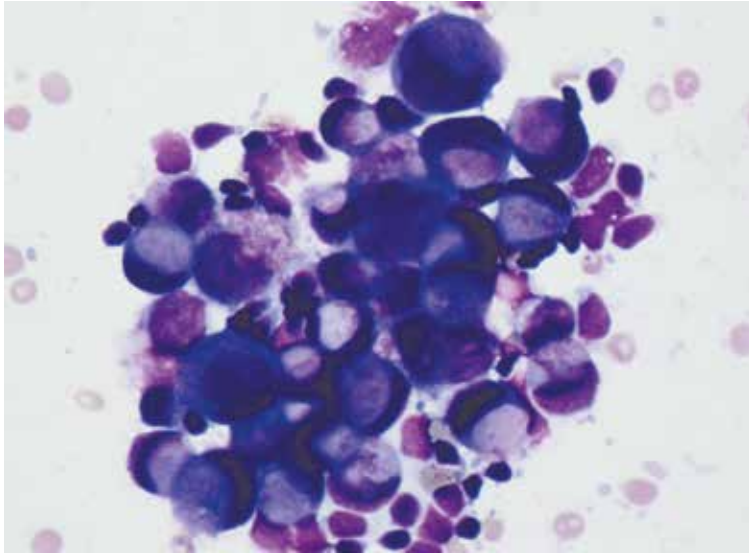


Figura 1. Fine needle aspiration of the umbilical node showed ring cells of adenocarcinoma Diff-Quick.

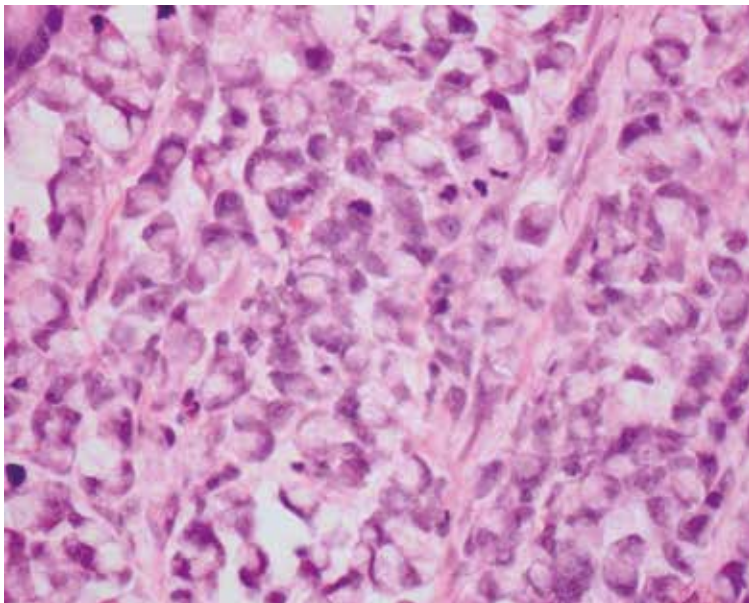


Figura 2. Ring cell adenocarcinoma in the cardia H.E.

from the primary liver tumor to the umbilicus through the portal system and then through the lymphatic and/or venous channels. It is still unclear if the umbilical tumor spread precedes the hepatic spread or *vice versa*.

Renal cell carcinoma typically spreads via extra-renal extension, lymphatic dissemination, or venous invasion by the tumor. Intraperitoneal spread may occur as a result of disruption of the renal capsule. The dissemination of neoplastic cell through the urachus is assumed to be the mechanism for the bladder cancers^{19,20}.

Haematogenous, lymphatic, and venous spread all represent valid mechanisms of tumour spread from gynaecological cancers.

Sister Mary Joseph's nodule represents cutaneous metastasis in the umbilical region, where most cases are due to intra-abdominal neoplasia, especially gastric adenocarcinoma²¹⁻²³.

When this lesion is found, it is important to perform a complete clinical examination, histological diagnosis by fine needle aspiration biopsy, and imaging studies in order to look for the primary tumor.

Even though it has been associated with ominous prognosis, recent studies suggest that in selected cases, aggressive surgical approach combined with chemotherapy may be considered to improve the patient's survival²³⁻²⁵. ■

REFERENCES

1. Galvañ VG. Sister Mary Joseph's nodule. *Ann Intern Med.* 1998 ;128(5):410.
2. Cohen DC. A man with an umbilical ulcer. *Medscape J Med.* 2008;10(1):11.
3. Kasper D, Braunwald E, Hauser S, Longo D, J, Jameson L, Fauci A, *et al.* Principles of internal medicine. 16. ed. New York: McGraw –Hill; 2004.
4. Bailey H. Demonstration of physical signs in clinical surgery. 11. ed. Baltimore: Williams & Wilkins; 1949.
5. Schwartz IS. Sister (Mary?) Joseph's nodule. *N Engl J Med.* 1987; 21;316(21):1348-9.
6. Bailey H. Demonstrations of physical signs in clinical surgery. 11. ed. Baltimore: Williams & Wilkins; 1949.
7. Hill M, O'Leary JP. Sister Mary Joseph and her node. *Am Surg.* 1996; 62: 328-329.
8. Trebing D, Goring HD. The umbilical metastasis: Sister Mary Joseph and her time. *Hautarzt.* 2004; 55:186-189.
9. Lookingbill D, Spangler N, Sexton FM. Skin involvement as the presenting sign of internal carcinoma. A retrospective study of 7316 cancer patients. *J Am Acad Dermatol.* 1990; 22:19-26.
10. Steck WD, Helwig EB. Tumors of the umbilicus. *Cancer.* 1965; 18:907-915.
11. Touraud JP, Lentz N, Dutronc Y, Mercier E, Sagot P, Lambert D. Umbilical cutaneous metastasis (or Sister Mary Joseph's nodule) disclosing an ovarian adenocarcinoma. *Gynecol Obstet Fertil.* 2000; 28:719-721.
12. Barrow MV. Metastatic tumors of the umbilicus. *J Chron Dis.* 1966; 19:1113-
13. Galvañ VG. Sister Mary Joseph's nodule. *Ann Intern Med.* 1998; 128:410.
14. Falchi M, Cecchini G, Derchi LE. [Umbilical metastasis as first sign of cecal carcinoma in a cirrhotic patient (Sister Mary Joseph nodule). Report of a case]. *Radiol Med.* 1999;98(1-2):94-6.
15. Gabriele R, Borghese M, Conte M, Basso L. Sister Mary Joseph's nodule as a first sign of cancer of the cecum: report of a case. *Dis Colon Rectum.* 2004; 47:115-117.
16. Ching A, Lai CW. Sonography umbilical metastasis (Sister Mary Joseph's nodule): from embryology to imaging. *Abdom Imaging.* 2002; 27:746-749.
17. Jager RM, Max MH. Umbilical metastasis as the presenting symptom of cecal carcinoma. *J Surg Oncol.* 1979; 12:41-45.
18. Majmudar B, Wiskind AK, Croft BN, Dudley AG. The Sister (Mary) Joseph nodule: it's significance in gynaecology. *Gynecol Oncol.* 1991; 40:152-159.
19. Dornier C, Reichert-Penetrat S, Barbaud A, Kaise V, Schmutz JL. Nodule de soeur Marie-Joseph révélant un lymphome. *Ann Dermatol Venereol.* 2000; 127:732-734.
20. Chen P, Middlebrook MR, Goldman SM, Sandler CM. Sister Mary Joseph nodule from metastatic renal cell carcinoma. *J Comput Assist Tomogr.* 1998; 22:756-757.
21. Khan AJ, Cook B. Metastatic carcinoma of umbilicus. "Sister Mary Joseph's nodule". *Cutis.* 1997; 60:297-298.
22. Poncelet C, Bouret JM, Boulaj I, Tsatsaris V, Ferrand J, Mintz JP, *et al.* Umbilical metastasis of an endometrial adenocarcinoma: "Sister (Mary) Joseph's nodule". Review of the literature. *J Gynecol Obstet Biol Reprod (Paris).* 1996; 25:799-803.
23. Panaro F, Andorno E, Di Domenico S, Morelli N, Bottino G, Mondello R, *et al.* Sister Joseph's nodule in a liver transplant recipient: Case report and mini-review of literature. *World J Surg Oncol.* 2005; 3:4.
24. Requena Caballero L, Vazquez Lopez F, Requena Caballero C, Urrutia Hernando S, Sanchez Lopez M, Sanchez Yus E, *et al.* Metastatic umbilical cancer – Sister Mary Joseph's nodule: Report of two cases. *J Dermatol Surg Oncol.* 1988; 14:664-667.